

## The Possible Protective Effect of Melatonin and Coenzyme Q10 on Lung Injury Induced by Bleomycin in Adult Male Albino Rats

Amal Mahmoud ElSafy Elshazly<sup>1</sup>, Bodour Qassim BadrEldeenBaoumy<sup>1</sup>,

Yasmeen Mohammed Ismail El Sayed<sup>2</sup>, Asmaa Y.A. Hussein<sup>3</sup> and Hanan I. El-Kerdasy<sup>1</sup>

Department of Anatomy and Embryology<sup>1</sup>, Department of Clinical Pharmacology<sup>2</sup>,

Department of Forensic Medicine and Clinical Toxicology<sup>3</sup>, Faculty of Medicine, Benha University

Corresponding author: Hanan I El-Kerdasy, 01007618122, [mhanan909@yahoo.com](mailto:mhanan909@yahoo.com)

### ABSTRACT

**Background:** bleomycin-induced lung toxicity and oxidative damage by decreasing the deactivating enzyme, genetic vulnerability, and released cytokines of inflammation. Melatonin has a free radical detoxifying effect, coenzyme Q10 has a strong antioxidant effect. **Aim of the study:** this study aimed to evaluate the possible protective role of melatonin and coenzyme Q10 in bleomycin-induced lung injury in Albino rats. **Material and Methods:** forty male Albino rats were categorized into five groups; group I (control group), group II (bleomycin group): rats were given a single dose of bleomycin intra-tracheal for inducing lung injury, group III (melatonin group): rats were given melatonin for three weeks after intratracheal installation of bleomycin, group IV (coenzymeQ10 group): rats were given coenzymeQ10 for three weeks after intratracheal installation of bleomycin and group V (combined melatonin and Co Q10 group): rats were given a combination of melatonin and coenzyme Q10for three weeks after induction of bleomycin lung toxicity. Lung tissues were prepared for biochemical, histological and immunohistochemical studies.

**Results:** bleomycin produced a significant increase in the level of malondialdehyde and a significant reduction in glutathione peroxidase activity in lung tissues with loss of normal histological lung architecture, significant elevation in main area percent of collagen fibers deposition and caspase-3 immuno positive expression. In group III melatonin enhanced a significant improvement in the biochemical changes, moderate prevention of histopathological changes in lung tissue with a significant reduction in main area percent of collagen fibers deposition and caspase-3 immuno positive expression. While, in group IV co enzyme Q10 enhanced non significant improvement in the biochemical changes, mild prevention of histopathological changes and non-significant reduction in main area percent of collagen fibers deposition and caspase-3 immuno positive expression. Using a combination of both drugs in group V enhanced a significant improvement in the biochemical changes and almost preservation of normal histological architecture of the lung tissue. **Conclusion:** administration of both melatonin and coenzyme Q10 produced almost a complete recovery of bleomycin induced lung injury.

**Key words:** bliomycin, melatonin, Co enzyme Q10, lung toxicity.

### INTRODUCTION

Bleomycin is an initial chemotherapeutic drug used for treatment of tumors for years ago. It considered the first chemotherapeutic drug used in treatment of Hodgkin's lymphoma and germinative tumors<sup>(1)</sup>. Bleomycin was taken in treatment of tumors for a long time and mostly involving the young age. Prescription of bleomycin must be followed by awareness of early diagnosis and prevention of its potential pulmonary toxicity, especially in long duration of administration of bleomycin as it caused a dose-dependent interstitial pulmonary fibrosis<sup>(2)</sup>. Bleomycin was initially biosynthesis from *Streptomyces verticillus* fungus<sup>(3)</sup>. It mostly caused an entry of granulocytes into the tissue, that release reactive oxygen species like hydroxyl radicals, superoxide radical, and hydrogen peroxides, furthermore proteolytic enzymes together with a rise in oxidant generation and macrophages<sup>(4)</sup>. Another study concluded that intra-tracheal inhalation of bleomycin in rodent animals caused histopathological changes in the lung tissue as it induced fibroblast proliferation, alveolar destruction, an inflammatory cell infiltration and extracellular matrix deposition, similar to human fibrotic lung disease<sup>(5)</sup>. Melatonin is a neurohormone

secreted at the night from the pineal gland. Recently, it was identified as anti-tumor genesis, sleep regulation, immune adjustment and a powerful antioxidant<sup>(6)</sup>. Melatonin has anti-fibrotic effects through the pathogenesis of fibrosis, melatonin induced inhibition of leptin-induced augmentation of collagen type 1. Also, melatonin regulated the connective tissue growth factor, fibronectin and transforming growth factor  $\beta$ <sup>(7)</sup>. Coenzyme Q10is documented as a dominant systemic antioxidant that prevented the oxidative injury occurs in the essential molecules like DNA, lipids, and proteins<sup>(8)</sup>. Co Q10 is synthesized in the mitochondria of vital organs as heart, liver and lungs<sup>(9)</sup>.

This study aimed to evaluate the effects of melatonin, Coenzyme Q10 and combination of both of them on pulmonary injury induced by bleomycin.

### MATERIAL and METHODS

#### The experimental animals:

Forty male Albino rats about  $180 \pm 20$  g body weight, from the animal house, Moshtohor Faculty of Veterinary Medicine, Benha University; rats were kept in suitable temperature under 12 hr light/dark cycle. The



This article is an open access article distributed under the terms and conditions of the Creative Commons Attribution (CC BY-SA) license (<http://creativecommons.org/licenses/by/4.0/>)

animals were housed for ten days and were given basal diet prior to the experimental study.

**Ethical approval:**

This experimental study was reviewed and conducted in accordance with the Research Ethical Committee Recommendations of Faculty of Medicine, Benha University.

**Drugs:**

**Bleomycin hydrochloride** in the form of Bleocin 15 mg vial obtained from Nippon Kayaku Company Ltd-Japan imported by Selides Pharma. The bleomycin was dissolved in saline 0.9%.

**Melatonin** was obtained from Nature's Bounty, USA Company, tablets, each tablet contained 3 mg of melatonin, and tablets were crushed then dissolved in 1% ethanol.

**Coenzyme Q10** was obtained from Arab Company for Pharmaceuticals and Medicinal Plants- Egypt; each capsule contained 30mg of Coenzyme Q10 then dissolved in 0.4 ml of 0.9 % NaCl + corn oil.

Rats were categorized equally in to five groups each contained eight rats as following:

**Group I (Control):** the rats were anesthetized by chloroform, then a mid-line incision in the skin overlying the trachea was made and given single intratracheal injection of saline 0.9% and kept for three weeks.

**Group II (Bleomycin group):** the rats were anesthetized by chloroform, then a mid-line incision in the skin overlying the trachea was made and given single intratracheal injection of Bleomycin at a dose of 5 mg/kg for inducing lung injury <sup>(10)</sup> and kept for three weeks after bleomycin instillation.

**Group III (Melatonin-treated group):** rats were given bleomycin dose as in group II, then, after 24 h from that dose, rats were given melatonin at a dose of 5 mg/kg daily intraperitoneal for three weeks <sup>(10)</sup>.

**Group IV (Coenzyme Q10-treated group):** rats were given bleomycin dose as in group II, then, after 24 h from that dose, rats were given coenzymeQ10 at a dose of 4mg/kg daily intraperitoneal for three weeks <sup>(11)</sup>.

**Group V (Melatonin and coenzyme Q10-treated group):** rats were given bleomycin dose as in group II, then, after 24 h from that dose, rats were given combination of melatonin and coenzyme Q10 with the same dose as in group III and group IV respectively daily for three weeks. All animals were sacrificed by an overdose of ether. Midline abdomen thoracic incision was done and the lungs were dissected; the right lungs were washed with 10 ml of 0.9% saline to remove blood, and stored in a freezer for biochemical analyses.

Left lungs were prepared for the histopathological examination.

**Biochemical analyses:**

Samples of right lungs were perfused to remove any red blood cells and clots, then homogenized in 0.9% saline solution, centrifuged at 3000 rpm for fifteen min, and the supernatant was stored at -20°C until determination of lung malondialdehyde (MDA) the breakdown product of lipid peroxidation that was determine lipid peroxidation <sup>(12)</sup> and lung glutathione peroxidase (GSH-Px) level was analyzed by using a commercial kit (Biodiagnostic, Egypt) <sup>(13)</sup>.

**Histological study:**

The left lung samples were fixed in 10% formalin, then embedded in paraffin and sliced as 5-µm-thick sections then stained with hematoxylin and eosin (H&E). Mallory trichrome stain was used for determination of collagen fibers in the lung tissue <sup>(14)</sup>. Caspase-3 immune-histochemical was used according to the standard avidin-biotin peroxidase complex system followed by diaminobenzidine (DAB) visualization <sup>(15)</sup>.

**Morphometric study**

Area percent of collagen fibers deposition and caspase-3 immune-positive stains were determined by image analysis software program (Image j. 1.46version) in 10 randomly selected different microscopic fields at a magnification of X 200 for each specimen.

**Statistical analysis**

Data were statistically analyzed using SPSS software Version 20. All data were represented as the mean ± standard deviation (SD) by using One-way analysis and t-test, with P≤0.01 as the level of statistical significance.

**RESULTS**

**Biochemical analysis (Table 1):**

MDA level showed a significant elevation (P ≤ 0.01) in group II in comparison with that in the control group, while it was significantly decreased in group III and group V in comparison with group II (P ≤ 0.01), but it showed non significant decrease in group IV in comparison with that in group II

The activity of GSH-Px showed a significant decrease (P ≤ 0.01) in group II in comparison with that in the control group, However, it was significantly increased in group III and group V in comparison with group II (P ≤ 0.01). But, it showed non significant increase in group IV in comparison with group II

**Table 1: changes in MDA and GSH-Px levels ± SD in all groups**

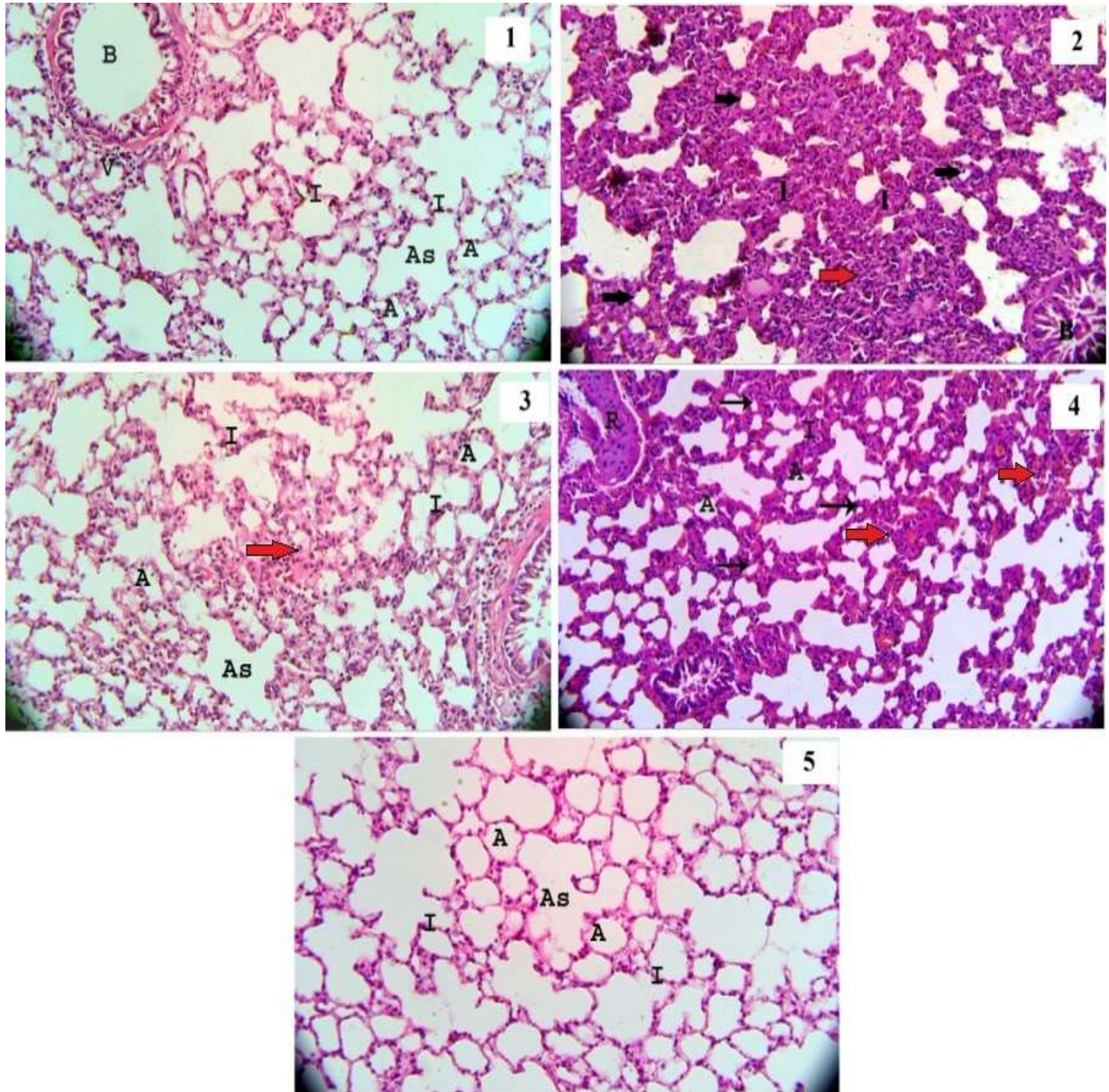
Main % ± SD	Group I	Group II	Group III	Group IV	Group V
MDA(nmol/g tissue)	14.8± 0.4	35.2± 0.41	21.5± 0.48	29.9± 0.46	17.3± 0.58
GSH-Px (u/mg tissue)	7.3± 0.42	2.2± 0.35	5.4± 0.31	3.1± 0.33	6.17±0.32
Significance≤ 0.01	With group II& IV	With groups I,III&V	With groups II, IV	With groups I, III& V	With groups II, IV

**Histological result:**

**Hematoxylen and Eosin staining:**

H&E-stained lung sections from group I showed normal lung architecture, normal alveoli with thin inter alveolar septum, alveolar sac, bronchioles lined by normal epithelial cells and normal blood vessels (Fig.1). In group II, there was loss of normal lung architectures, many collapsed alveoli, marked inflammatory cell infiltration, marked thickened alveolar septa and partial obliterated bronchiole (Fig.2).

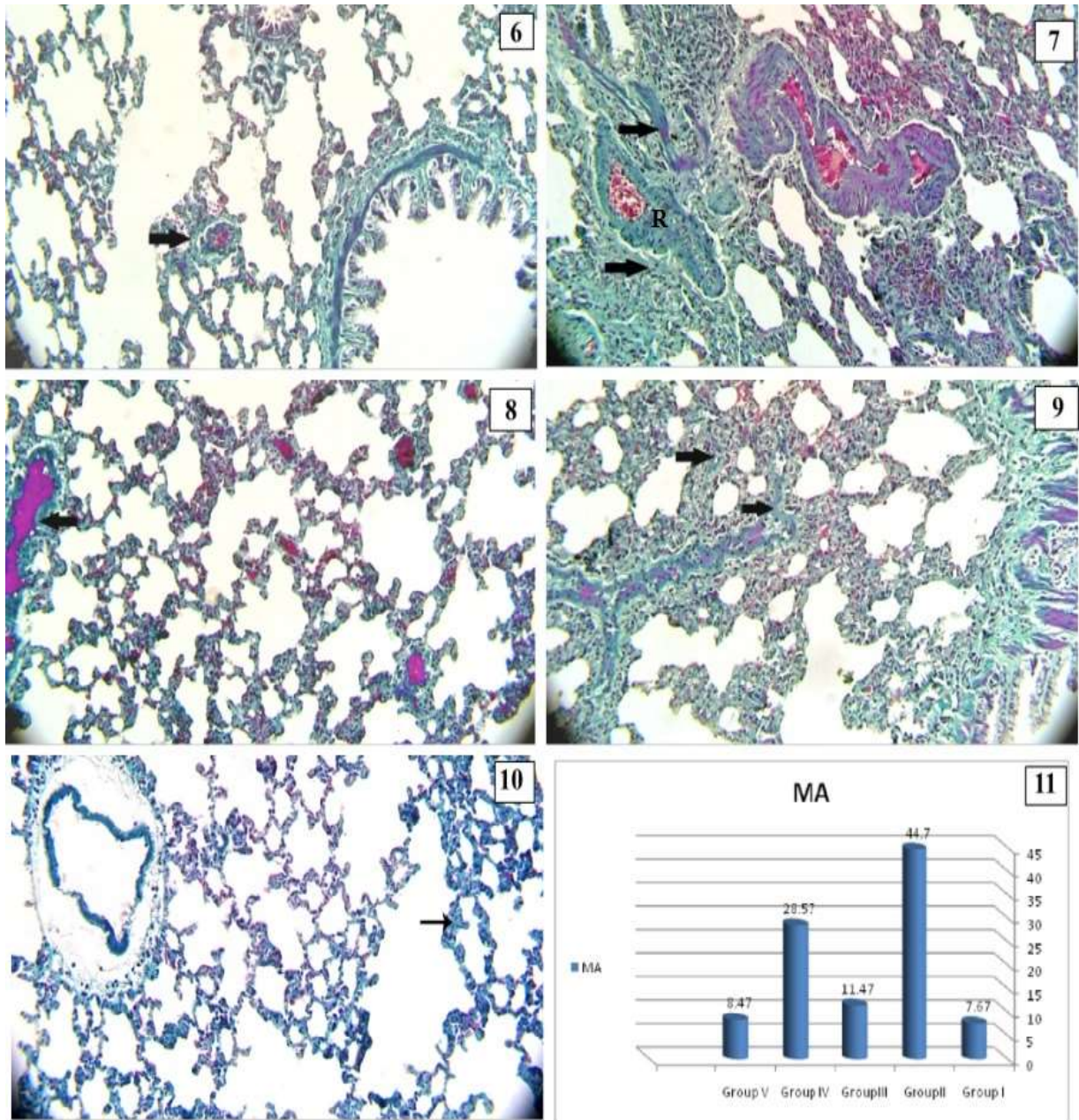
In group III, lung section showed normal alveoli with mild thickened inter alveolar septum and normal alveolar sacs with mild inflammatory cell infiltration (Fig.3). In group IV lung section showed collapsed alveoli, some patent alveoli, moderate inflammatory cell infiltration, moderate thickened inter alveolar septum with highly thickened and corrugated arterial wall (Fig. 4). Group V showed normal lung tissue structures, normal alveoli with thin inter alveolar septum and normal alveolar sacs (Fig. 5).



Photomicrographs of lung sections stained by H&E- Fig1: group I showing normal lung architectures, alveoli (A), thin inter alveolar septa (I), normal alveolar sac (AS), bronchiole lined by normal epithelial cells (B) and normal blood vessel (V). Fig 2: group II showing loss of normal lung architectures, many collapsed alveoli (black arrow), marked inflammatory cell infiltration (red arrow), and marked thickened alveolar septa (I), partial obliterated bronchiole (B). Fig 3: m group III showing normal alveoli (A) with mild thickened septa (I) normal alveolar sac (AS), mild inflammatory cell infiltration (red arrow) Fig 4: group IV showing collapsed alveoli (black arrow), patent alveoli (A), moderate inflammatory cell infiltration (red arrow), and moderate thickened alveolar septa (I) highly thickened and corrugated arterial wall (R). Fig 5: group V showing normal alveoli (A) thin interalveolar septa (I),normal (AS) alveolar sac (H&E x 200).

**Mallory's trichrome stain:**

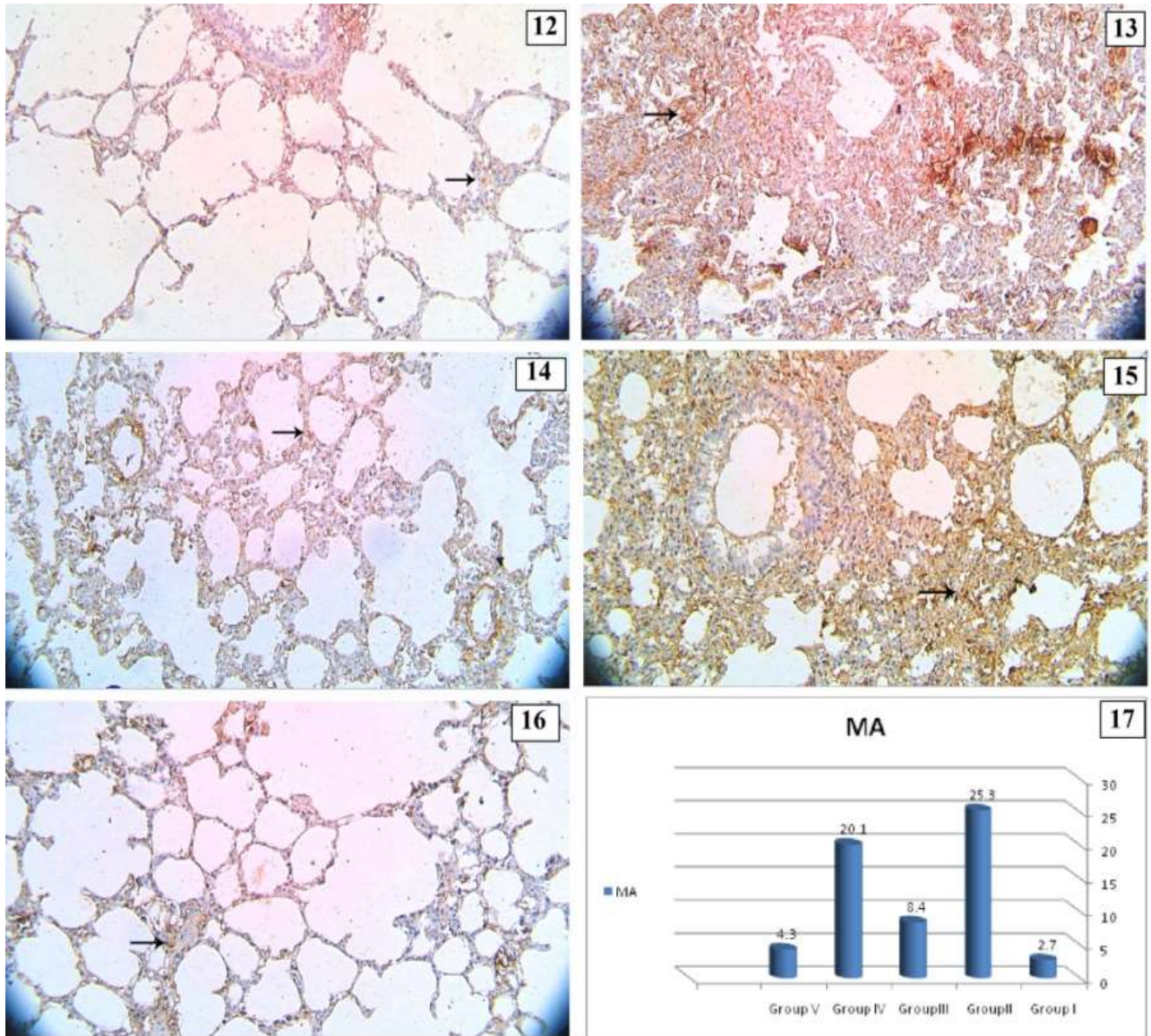
Group I showed scanty collagen fibers deposition around the blood vessel (Fig.6), but in group II there was marked accumulation of collagen fibers around the bronchiole and in the highly thickened and corrugated arterial wall (Fig. 7). While, in group III, there was mild accumulation of collagen fibers around the blood vessel (Fig. 8), and moderate deposition of collagen fibers in group IV in alveolar wall (Fig. 9). Furthermore, there was scanty deposition of collagen fibers in group V; the collagen fibers distribution appeared as those detected in the control group (Fig.10).



Photomicrographs of lung sections stained by Mallory's trichrome. Fig 6: group I showing scanty collagen fibers (arrow) around the blood vessel. Fig 7: group II showing marked collagen fibers deposition (arrow) around the bronchiole and in the highly thickened and corrugated arterial wall (R). Fig 8: group III showing mild collagen fibers deposition (arrow) around the blood vessel. Fig 9: group IV showing moderate collagen fibers (arrow) in the alveolar wall. Fig 10: in group V showing scanty collagen fibers (arrow) in alveolar wall (Mallory's trichrome, x200). Fig 11: a histogram showing the mean area percent of collagen fibers deposition in groups I, II, III, IV and V.

**Caspase-3 Immuno-histochemical staining:**

Caspase-3 immunostain indicated the degree of cell apoptosis that demonstrated as brown cytoplasmic stain. Lung section from group I showed few positive caspase-3 expressions in cytoplasm of the alveolar lining cells (Fig. 12). But, in group II, there was highly positive caspase-3 expression (Fig.13). Lung section from group III, showed mild positive caspase-3 expression (Fig. 14), while in group IV, there was moderate caspase-3 expression (Fig. 15). However, in group V there was few caspase-3 expression in the alveolar lining cells (Fig.16).



Photomicrographs of lung sections stained by Caspase-3 immunostain. Fig 12: From group I showing few caspase-3 immuno positive expression (arrow) in cytoplasm of the alveolar lining cells. Fig 13: From group II showing highly caspase-3 immunopositive expression (arrow). Fig 14: From group III showing mild caspase-3 immuno positive expression (arrow). Fig 15: From group IV showing moderate caspase-3 immuno positive expression (arrow). Fig 16: From group V showing few caspase-3 immuno positive expression (arrow) (Caspase-3 x 200). Fig 17: a histogram showing the mean area percent of caspase-3 immuno positive expression in groups I, II, III, IV and V.

The mean area percent of collagen fibers deposition in lung sections for all groups was represented in table 2 & figure 11 and the mean area percent of caspase-3 expression in lung sections was represented in table 3 & figure 17. There was a significant elevation in main area percent of collagen fibers deposition and caspase-3 immuno-positive expression in group II in comparison with group I. There was a significant decrease in main area percent of collagen fibers deposition and caspase-3 immuno-positive expression in group III and V in comparison with that in group II. While, there was non significant decrease in main area percent of collagen fibers deposition and caspase-3 immuno-positive expression in group IV in comparison with that in group II.

**Morphometric results:**

**Table 2: table showing mean values of area percent of collagen fibers deposition ± SD in all groups**

Main % ± SD	Group I	Group II	Group III	Group IV	Group V
MA	7.67±2.4	44.7±8.8	11.47±3.3	28.57±7.8	8.47±2.7
Significance ≤ 0.05	With group II & IV	With groups I, III & V	With groups II, IV	With groups I, III & V	With groups II, IV

**Table 3: table showing mean values of area percent of caspase-3 immuno- positive expression ± SD in all groups**

Main % ± SD	Group I	Group II	Group III	Group IV	Group V
MA	2.7±0.35	25.3± 6.7	8.4± 4.4	20.1± 1.8	4.3± 0.3
Significance ≤ 0.05	With group II& IV	With groups I,III&V	With groups II, IV	With groups I, III& V	With groups II, IV

## DISCUSSION

Bleomycin is a successful chemotherapeutic drug against a variety of malignancies, however the mortality of bleomycin-induced pulmonary toxicity was noticed, and bleomycin administration led to a decrease in the antioxidant enzymes activity and increase in lipid peroxidation in lung tissue (16). Melatonin improved pulmonary function, and regulated the senescence-associated secretory phenotype (SASP) in fibroblast cells of human fetal lung. Melatonin has an effective role in chronically hypoxic rat model in reducing the pulmonary hypertension (17). Coenzyme Q10 prevented the progress of fibrosis through its anti-inflammatory and antioxidant activity caused by its role in reducing Tumor Necrotic Factor alpha, Transforming Growth Factor Beta and Monocyte Chemoattractant Protein 1 MCP1 in lung tissues (18).

This work was designed to evaluate the effect of melatonin and coenzyme Q10 and combination of both drugs in elimination the lung injury induced by bleomycin.

In this study bleomycin exerted a significant increase in MDA level compared to the control group and a significant reduction in GSH-Px activity that produced changes in biochemical analysis in lung tissue and oxidative stress. These findings are in agreement with Çelikezen *et al.* (11) who proved that bleomycin has immunosuppressive and anti-neoplastic effect but also caused toxicity and changes in biochemical markers in lung in experimental animal studies. Ayman (19) showed that bleomycin induced oxidative stress by increasing lipid peroxidation. Another study showed that the accumulation of neutrophils was the main cause of lung fibrosis induced by bleomycin in human and rat model and recommended the role of antioxidant compounds in reducing the level of neutrophils for protection of lung tissue (20). Farther more, Alia *et al.* found that a single intratracheal injection of bleomycin induced a significant increase in lung MDA level, and serum TGF-β1 level compared with control group (21).

In this study bleomycin produced loss of normal lung architectures with many collapsed alveoli, marked inflammatory cell infiltration, marked thickened alveolar septa and partial obliterated bronchiole and significant increase in main area percent of collagen fibers deposition and caspase-3 immuno-positive expression in comparison with that in group I. This result is in agreement with a previous histopathological study which detected

loss of lung architecture in most of lung sections from bleomycin group, and replacement of the lung tissue with fibrous tissue (22). Similarly Parlari *et al.* added that bleomycin induced areas of necrosis and inflammation in lung sections with increased the accumulation of collagen fibers and extracellular matrix especially peribronchial (23). In the same line, Alia, *et al.* (21) found that the histopathological study of bleomycin group showed a significant increase in fibrosis score, adding together to, a significant increase in H-score of fibrosis of α-SMA immuno-histochemical stain compared to the control group.

Melatonin administration led to a significant reduction in MDA level and a significant elevation in GSH-Px activity in lung tissue in comparison with that in the bleomycin group. This is in agreement with Genovese *et al.* (24) who added that melatonin decreased reactive oxygen species production and non-selective melatonin receptor antagonist that prevented the apoptosis in the lung tissue. Another study confirmed that the antioxidant effect of melatonin may be due to its direct free radical detoxifying activity (25). A recent study on the effect of melatonin in treatment of respiratory diseases of Covid 19 virus found that melatonin has a good role in reducing the release of pro-inflammatory cytokines so it is able to eliminate different high grade inflammations (26).

Our study proved the protective effect of melatonin by the histological examination of the lung sections that showed moderate preservation of normal lung architectures and a significant reduction in main area percent of collagen deposition and caspase-3 immuno-positive expression this is in agreement with (7), who added that melatonin protect against fibrosis of the lung and indicate that melatonin therapy could be a recent line for treatment of lung fibrosis. Also, Zhang *et al.* found the same result as melatonin abolished the harmful effects of bleomycin, and maintained the structure of mitochondria and epithelial cells lining the alveoli (10). Zhao *et al.* stated that melatonin has protective role against lung fibrosis induced by bleomycin in the mice by its inhibition of endoplasmic reticulum stress and epithelial mesenchymal transition. This encourages using melatonin in prevention and treatment of lung fibrosis caused by bleomycin (27).

In this study administration of co enzyme Q10 led to non significant reduction in MDA level and non significant elevation in GSH-Px activity compared

with that in bleomycin group. This indicated the mild protective effect of co enzyme Q10 against bleomycin lung injury. In the same line **Gokce et al.**<sup>(28)</sup> confirmed that coenzyme Q10 had an important role in membrane stabilization by its strong antioxidant activity. Also, it prevented reaction of peroxidation chain and scavenges oxygen free radicals. So, it inhibited lipid peroxidation. Similarly, **Olama et al.**<sup>(9)</sup> revealed that coenzyme Q10 had a protective role on lung tissue against cyclophosphamide injurious effect in rats. However, **Lim et al.** found that Co Q 10 didn't improve the peak airway pressure and the arterial oxygen in severing lung ischemia-reperfusion that could happen in lung transplantation<sup>(29)</sup>.

In the present study co enzyme Q10 led to mild improvement in the histo-pathological changes induced by bleomycin and there was a non significant reduction in main area percent of collagen deposition and caspase-3 immuno-positive expression this is in agreement with<sup>(11)</sup> who found that boric acid and CoQ10 improved the ultra-structures of lung tissue. Also **Mohamed et al.** detected the protective properties of CoQ10 in regulation the autophagy pathway that give explanation by its role in prevention of lung and liver fibrosis<sup>(30)</sup>.

In our study, combination of melatonin and coenzyme Q10 in treating the adverse effect of bleomycin produced a significant reduction in lung tissue MDA level and a significant elevation in GSH-Px activity in comparison with bleomycin group. The histological finding showed almost complete improvement of lung sections from group V and a significant reduction in main area of collagen deposition and caspase-3 immuno-positive expression in compared to bleomycin group. The results indicated that using a combination of melatonin and coenzyme Q10 could be able to enhance a complete recovery of lung tissue from the injury induced by bleomycin.

Another study proved the protective role of a combination of melatonin and co enzyme Q10 after ochratoxin administration in kidney and liver tissue sections in rats<sup>(8)</sup>. Also, **Elbaky et al.**<sup>(31)</sup> stated that CoQ10 and N-Acetylcysteine had an ameliorative role in myocardial oxidative stress and encourages their use in protection from cardiotoxicity. **El-Ansary et al.** proved the role of melatonin and co enzyme Q10 in ameliorating the impaired fatty acid profile in rodent model of autism<sup>(32)</sup>.

**Conclusion:** melatonin had a higher protective effect than co enzyme Q10 in elimination the injury effect of bleomycin in lung tissue. While, administration of a combination of both drugs enhanced almost a complete recovery of lung tissue.

**Recommendation:** we recommended taking a combination of melatonin and co enzyme Q10 in patients treated with bleomycin.

## REFERENCES

1. **Reinert T, Baldotto C, Nunes Fet al. (2013):** Bleomycin-induced lung Injury. doi .org/10.1155 /2013/ 480608
2. **Banakh I, Lam A, Tiruvoipati R et al. (2016):** Imatinib for bleomycin induced pulmonary toxicity: a case report and evidence base review. Clin. Case Rep., 4(5):486-490.
3. **Brugge S, Claasen H and Dawson L (2013):** Drug induced lung injury a case of fatal bleomycin interstitial pneumonitis. Netherlands J. Critical Care,17: 25- 29.
4. **Fyfe A , McKay P (2010):** Toxicities associated with bleomycin. J. Coll. Physicians Edinb., 40(3):213- 215.
5. **Altintas N, Erboga M, Aktas Cet al. (2016):**Protective effect of infliximab, a tumor necrosis factor alfa inhibitor, on bleomycin induced lung fibrosis in rats. Inflammation, 39(1):65- 78.
6. **Hu W, Ma Z, Jiang Set al. (2016):**Melatonin: the dawning of a treatment for fibrosis? J. Pineal Res., 60(2):121-31.
7. **Zhao X, Sun J, Su Wet al. (2018):**Melatonin protects against lung fibrosis by regulating the Hippo/YAP pathway. Int. J. Mol. Sci.,19(4):1118-1125.
8. **Sutken E, Aral E, Ozdemir Fet al. (2007):** Protective role of melatonin and coenzyme Q10 in ochratoxin a toxicity in rat liver and kidney. Int. J.Toxicol., 26(1):81-87.
9. **Olama N, Taha M and Rady H (2018):**The potential protective role of coenzyme q10 on the cyclophosphamide-induced lung toxicity in adult male albino rats: a histological and ultrastructural study. International Journal of Scientific Reports, 4(9):225-234.
10. **Zhang L, Li F, Su X et al. (2019):**Melatonin prevents lung injury by regulating apelin 13 to improve mitochondrial dysfunction. Exp. Mol. Med., 51(73):1-12
11. **Çelikezen F, Oto G, Özdemiret Het al. (2012):**The antioxidant effect of boric acid and CoQ10 on pulmonary fibrosis in bleomycin induced rats. Journal of Science and Technol.,2: 27-31
12. **Ohkawa H, Ohishi N and Yagi K (1979):**Assay for lipid peroxides in animal tissues by thiobarbituric acid reaction. Analytical Biochemistry, 95:351– 358.
13. **Flohe L and Gunzler W (1984):** Assays of glutathione peroxidase. Methods Enzy., 105: 114-121.
14. **Bancroft JD and Layton C (2013):**Theory and Practice of Histological Techniques.7<sup>th</sup> ed., Churchill Livingstone of El Sevier. Philadelphia.pp: 172 - 214.
15. **Jackson P and Blythe D (2013):**Theory and Practice of Histological Techniques.7<sup>th</sup> ed., Churchill Livingstone of El Sevier. Philadelphia.pp:381 - 434.
16. **Ge V, Banakh I, Tiruvoipati R et al. (2019):**Bleomycin-induced pulmonary toxicity and treatment with infliximab: a case report. Clin. Case Rep., 6(10):2011-2014.
17. **Hung M, Yeung H, Lau Cet al. (2017):** Melatonin attenuates pulmonary hypertension in chronically hypoxic rats. Int. J. Mol. Sci., 18(6):1125. –1135.
18. **Tarry-Adkins J, Fernandez-Twinn D, Hargreaves Iet al. (2016):** Coenzyme Q10 prevents hepatic fibrosis,

- inflammation, and oxidative stress in a male rat model of poor maternal nutrition and accelerated postnatal growth. *Am. J. Clin. Nutr.*, 103(2):579-588.
- 19. Ayman M (2016):** Effect of pirfenidone on bleomycin induced pulmonary alveolar fibrosis in adult male rats. histological, immunohistochemical, morphometrical and biochemical Study. *International J. of Clinical and Developmental Ana.*, 2 (3): 17-23.
- 20. Williamson J, Sadofsky L and Hart S(2015):** The pathogenesis of bleomycin-induced lung injury in animals and its applicability to human idiopathic pulmonary fibrosis. *Experimental Lung Res.*, 41: 57–73
- 21. Alia E, Abd El Salama E, Dabaa Met al. (2018):**The effect of atorvastatin on bleomycin induced pulmonary fibrosis in rats. *Menoufia Medical Journal*, 31:1081–1087.
- 22. Sabry M, Elkalawy S, Abo-Elnour Ret al. (2014):**Histological and immunohistochemical study on the effect of stem cell therapy on bleomycin induced pulmonary fibrosis in albino rat. *Int. J. Stem Cells*, 7(1):33-42.
- 23. Parlar A, Arslan S, Yumrutas O et al. (2021):**Effects of cannabinoid receptor 2 synthetic agonist, AM1241, on bleomycin induced pulmonary fibrosis. *Biotech.Histochem.*, 96(1):48-59.
- 24. Genovese T, Paola D, Mazzon Eet al. (2005):**Melatonin limits lung injury in bleomycin treated mice. *J Pineal Res.*, 39(2):105-112.
- 25. Yildirim Z, Kotuk M, Erdogan Het al. (2006):** Preventive effect of melatonin on bleomycin-induced lung fibrosis in rats. *J. Pineal Res.*, 40(1):27-33
- 26. Hardeland R and Tan D (2020):** Protection by melatonin in respiratory diseases: valuable information for the treatment of COVID-19. *Melatonin Res.*, 3 (3)264-275.
- 27. Zhao H, Wu Q, Cao Let al. (2014):**Melatonin inhibits endoplasmic reticulum stress and epithelial-mesenchymal transition during bleomycin-induced pulmonary fibrosis in mice. doi: 10.1371/journal.pone.0097266.
- 28. Gokce M, Saydam O, Hanci Vet al. (2012):**Antioxidant vitamins C, E and coenzyme Q10 vs dexamethasone: comparisons of their effects in pulmonary contusion model. *J.Cardiothorac. Surg.*, 26:7:12.
- 29. Lim H, Jayaweera S, Calderone Aet al. (2010):**Protective role of coenzyme Q10 in two models of rat lung injury. *ANZ J. Surg.*, 80(4):265-270.
- 30. Mohamed D, Khairy E, Tawfek Set al. (2019):**Coenzyme Q10 attenuates lung and liver fibrosis via modulation of autophagy in methotrexate treated rat. *Biomed.Pharmacother.*, 109:892-901
- 31. Elbaky N, El-Orabi N, Fadda Let al. (2018):** Role of N-acetylcysteine and coenzyme Q10 in the amelioration of myocardial energy expenditure and oxidative stress, induced by carbon tetrachloride intoxication in rats. *Dose Response*, 16(3):1-7
- 32. El-Ansary A, Al-Ghamdi M, Bhat Ret al. (2016):**Potency of pre-post treatment of coenzyme Q10 and melatonin supplement in ameliorating the impaired fatty acid profile in rodent model of autism. *Food Nutr. Res.*,3(60):28127-28133.